

## Versatility of the Distally Based Hemigastrocnemius Muscle Flap for Covering Small to Medium Sized Middle Third Leg Defects

SHERIF M. ELKASHTY, M.D. and AHMED T. NASSAR, M.D.

*The Department of Plastic and Reconstructive Surgery, Faculty of Medicine, Menoufia University, Menoufia, Egypt*

### ABSTRACT

**Background:** Coverage of middle third leg defects is a reconstructive challenge. Distally based hemigastrocnemius muscle flap can be a valuable option in coverage of these defects. The vascular basis of this flap is the communicating vessels across the distal third or fourth of the raphe between the two heads.

**Aim of the Study:** To evaluate the use of the distally based hemigastrocnemius muscle flap for coverage of middle third leg defects.

**Patients and Methods:** This study was done at The Department of Plastic and Reconstructive Surgery, Menoufia University Hospitals, from January 2014 to March 2015, with a follow-up period of 12 months. It included 13 patients; all were males, and their age ranged from 23 to 51 years. All patients were presented with post-traumatic middle third leg defects. The defects were covered by a distally based medial gastrocnemius head in 11 patients, and a distally based lateral gastrocnemius head in 2 patients.

**Results:** All the flaps survived except one case showed marginal flap necrosis (7.6%). Skin graft take was complete except in 3 cases (23%) where there were partial losses. Infection occurred in 2 cases (15.3%) and managed conservatively. Donor site morbidity as functional deficit and contour irregularity were minimal. The flap provided durable and stable coverage during the follow-up period.

**Conclusion:** The distally based hemigastrocnemius muscle flap based on vascular communications between the two heads can be used for reconstruction of middle third leg defects. It provides a reliable and stable coverage of these defects without sacrificing a nerve or a major vessel to the foot. Donor site morbidity as functional deficit and contour irregularities are minimal.

**Key Words:** *Gastrocnemius – Muscle flap – Middle leg defects.*

### INTRODUCTION

A pretibial soft-tissue defect in the middle third of the leg represents a reconstructive challenge. There are many options for coverage of middle third including random local fasciocutaneous flaps, perforator fasciocutaneous flaps, local muscle flaps, cross-leg flaps and free tissue transfer [1,2,3].

Variable local muscle flaps became an established procedure in reconstruction of middle third leg defects, especially in the presence of osteomyelitis [4,5]. These muscle flaps include the proximally based soleus muscle flap [6], tibialis anterior muscle flap [7,8], and distally based hemigastrocnemius muscle flap [9,10], with each option having its advantages, disadvantages, and limitations.

The aim of this study is to evaluate the versatility of the distally based hemigastrocnemius muscle flap for coverage of post-traumatic small to medium-sized middle third pretibial leg defects.

#### *Relevant surgical anatomy:*

Tsetsonis et al. [11,12] in their cadaveric study examined the arterial communication between the gastrocnemius muscle heads through the lowest part of their raphe in fourteen fresh cadavers. Distinct communication between the arterial networks of the heads was demonstrated in all cases after injecting dyes through both sural arteries or into the lateral sural artery and the lowest anastomotic arteriole in 11 and 3 specimens, respectively. They concluded that one head can be adequately supplied from the contralateral one through their lowest anastomotic arteriole(s), located in the lower third or fourth of the raphe between the two heads.

### PATIENTS AND METHODS

This study was done at The Department of Plastic and Reconstructive Surgery, Menoufia University Hospitals. It was done in the period from January 2014 to March 2015, with a follow-up period of an average of 12 months. The study included 13 patients; all were males, and their age ranged from 23 to 51 years.

The defects were pretibial, small to medium-sized, located about the middle third of the leg, caused by motorcycle accidents, and associated

with fracture of the tibia or both bone of the leg. The fractures were fixed with either external or internal fixations by orthopedic surgeons and the patients were referred to our Plastic Department for soft tissue coverage.

#### *Surgical technique:*

All the procedures were performed under spinal anesthesia and tourniquet control. The patients were first placed supine where debridement of non viable and unstable tissues was done. Then, the patients were placed in the lateral decubitus, with the operated leg upwards, for ease of access. A straight skin incision in the middle of the upper calf region down to the deep fascia was done, extending from the popliteal crease proximally to the lower end of the gastrocnemius distally. The sural neurovascular pedicle originating from the popliteal vessels and posterior tibial nerve, for the selected gastrocnemius head to be used, was dissected, isolated, and divided. The selected head was then disinserted from its origin on the femoral condyle, and separated down from the other head along the intermuscular raphe, but preserving the most distal third or fourth of the raphe to preserve the vascular communications between the two heads. Scoring of the muscle fascia was done to increase its surface area. The short saphenous vein and the sural nerve were preserved during the dissection. The tourniquet was deflated and perfect hemostasis was done. Muscle flap viability was checked and non viable fibers, mostly the detached origin, if any, were debrided down to bleeding muscle fibers. The muscle flap was tunneled via a wide subcutaneous tunnel into the defect and sutured to the margins of the defect. Split-thickness skin graft was applied over the muscle flap either primarily or secondarily. The calf incision was closed over a suction drain that removed after 2 to 3 days, Figs. (1,2).

### RESULTS

This study included 13 patients; all were males, presented with post-traumatic small to medium-sized middle third leg defects. The defects were reconstructed by a distally based medial head gastrocnemius flap in 11 patients and a distally based lateral head gastrocnemius flap in 2 patients. The follow-up period was about 12 months.

All the flaps survived completely without flap loss. In one case (7.6%), there was marginal flap necrosis at the edge farther from the raphe communication, managed conservatively with debridement and frequent dressing and healed spontane-

ously. The skin graft take was complete, except in 3 cases (23%), where there were patchy graft losses, managed conservatively and healed spontaneously. There was neither post operative hematoma nor dehiscence of the calf incision. Infection at the original defect occurred in 2 cases (15.3%) and managed by culture-specific antibiotics and frequent dressing and healed uneventfully. No patients had sensory loss at the lateral aspect of the foot due careful preservation of the sural nerve.

As regards the donor site morbidity, there was no functional deficit and contour deformities were unappreciable. The muscle bulk decreases by time due to its denervation and there were no painful contractions for the same reason. The aesthetic appearance of the flap was satisfactory for all the patients and stable coverage by the muscle flap was obtained throughout the follow-up period, Figs. (1,2).

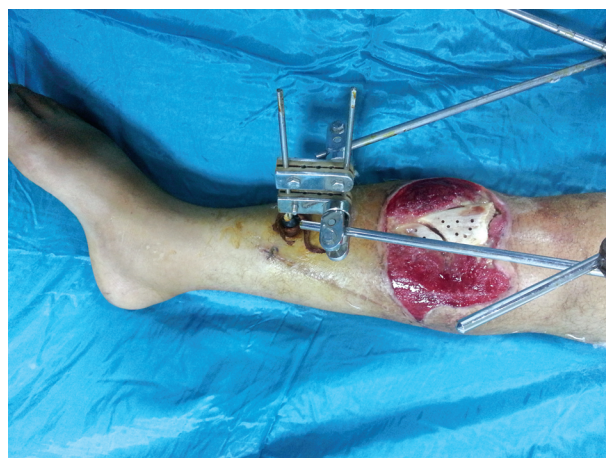


Fig. (1-A): Preoperative photo of Rt. leg middle third pretibial defect.

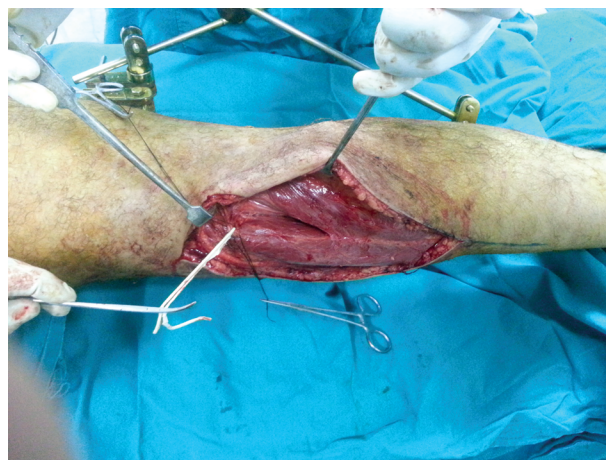


Fig. (1-B): Midline skin incision with dissection and isolation of the medial sural neurovascular pedicle that will be divided.



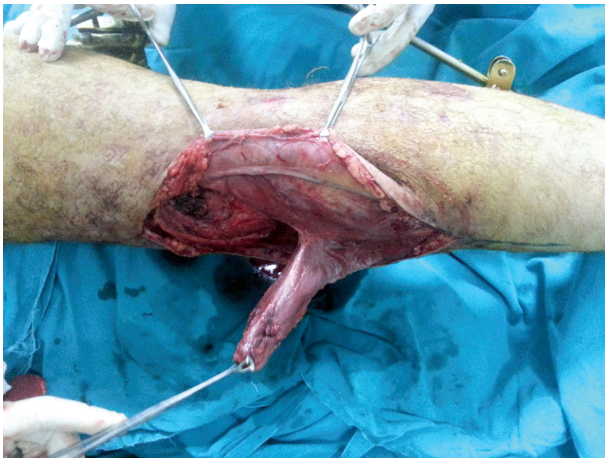


Fig. (1-C): Division of the medial sural neurovascular pedicle, detachment of the origin of the medial head, separating it from the lateral head along the raphe.

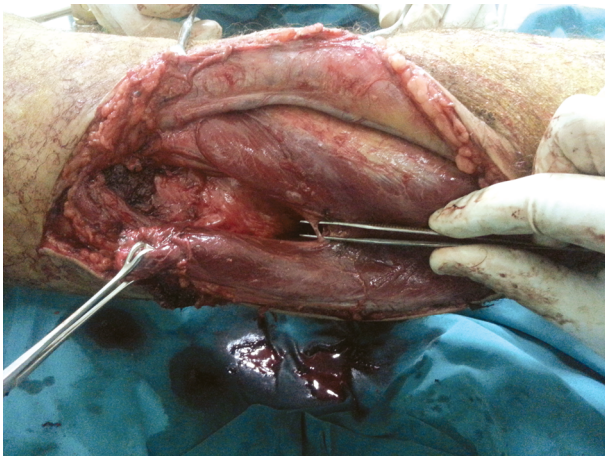


Fig. (1-D): Identification of the first communicating arteriole in the raphe between the 2 heads, shown here over the tips of forceps.

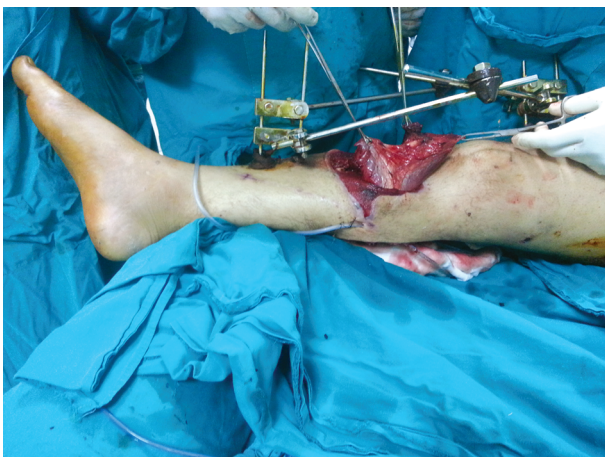

Fig. (1-E): The distally based medial head was delivered via a wide subcutaneous tunnel into the defect.

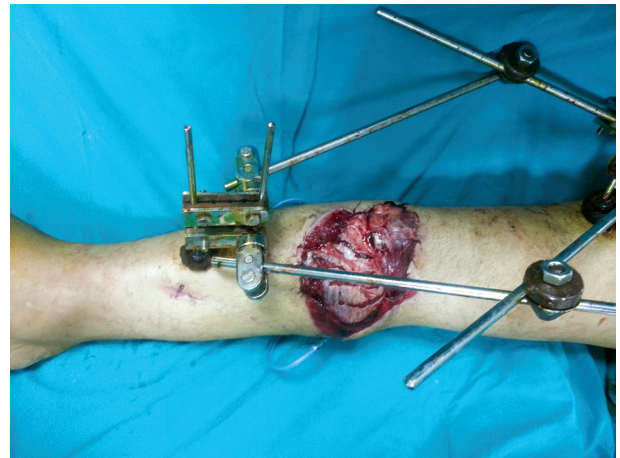


Fig. (1-F): The muscle fascia was scored and the muscle flap was sutured to the edges of the defect.

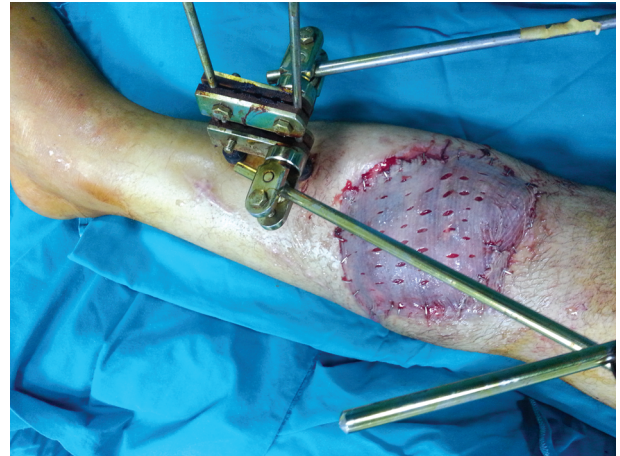


Fig. (1-G): The muscle flap was covered by a split-thickness skin graft.

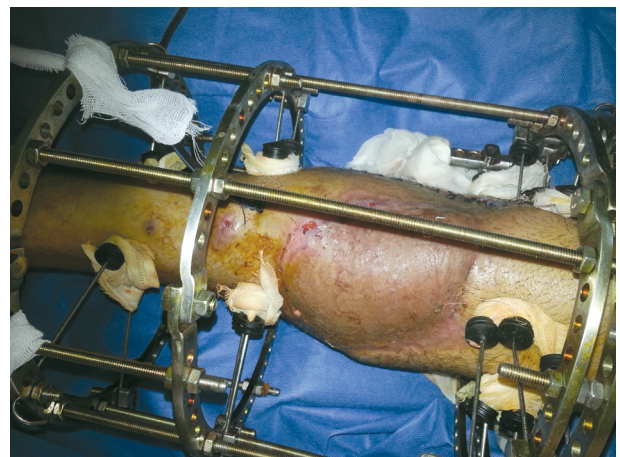


Fig. (1-H): A 3 months post-operative photo during completing orthopedic treatment. The muscle flap provided adequate stable coverage.



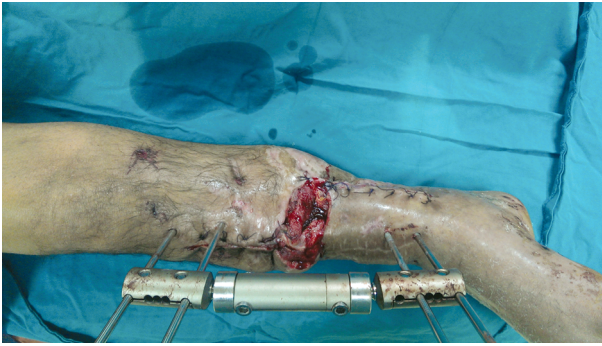

Fig. (2-A): Intra-operative photo of Rt. Leg with a defect at the junction of the middle and distal thirds with segmental loss of tibia after debridement by orthopedic surgeons.

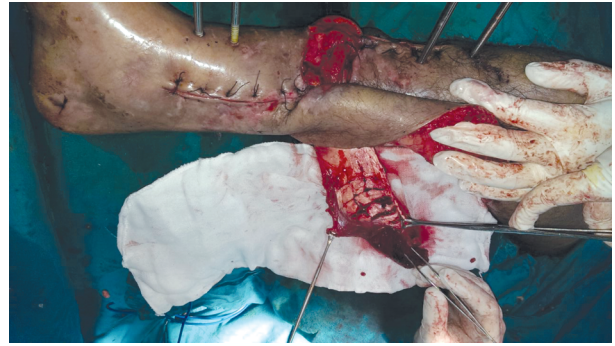

Fig. (2-D): The medial head detached from its origin down along the raphe with criss-cross scoring of the muscle fascia.

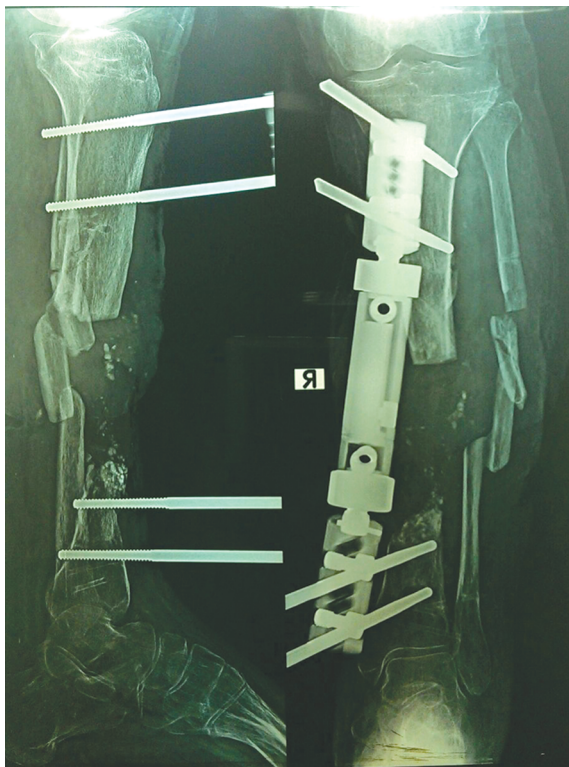


Fig. (2-B): X-ray of the Rt. leg showed fracture of tibia and fibula with segmental loss of the tibia.

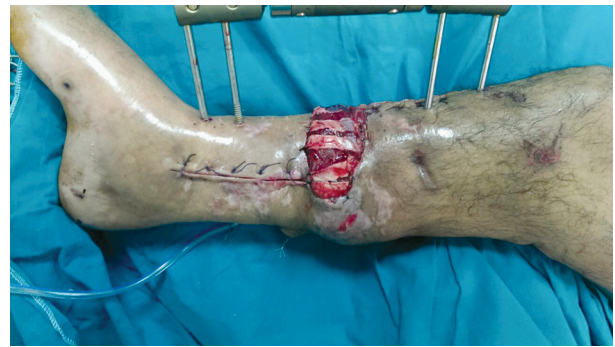

Fig. (2-E): The medial head muscle flap was delivered via a wide subcutaneous tunnel into the defect and sutured to its margin.

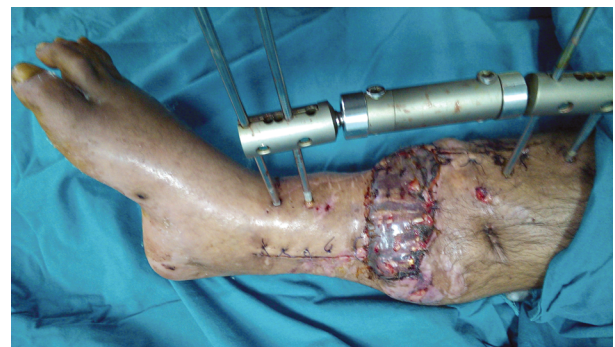


Fig. (2-F): A two-week post-operative photo of the skin grafted muscle flap.

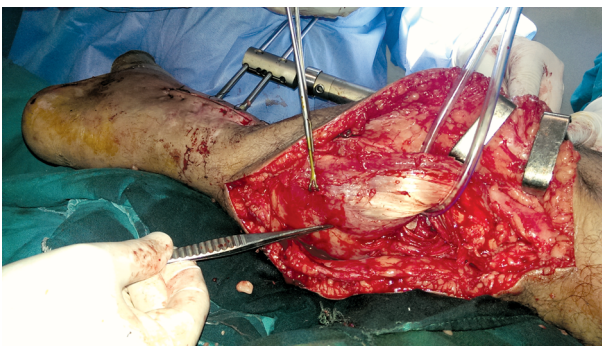


Fig. (2-C): Separation of the medial head off the lateral head along the raphe down to the intercommunicating vessels.

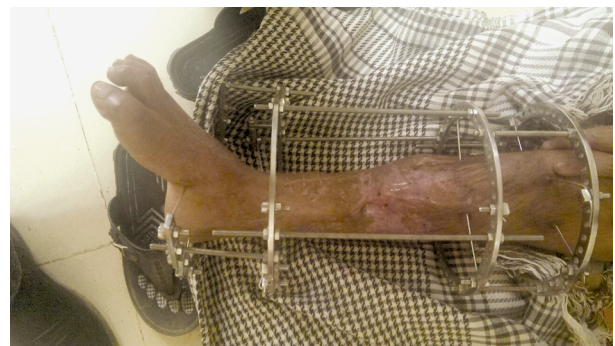

Fig. (2-G): A six-month post-operative photo after bone grafting of the segmental tibial loss and Ilizarov fixation. The muscle flap provided stable and durable coverage.



## DISCUSSION

Middle third pretibial soft tissue defects are frequently encountered in clinical practice. There are many coverage options including fasciocutaneous flaps, perforator fasciocutaneous flaps, muscle flaps, reversed sural flap, and free tissue transfer ect., with inherent advantages and disadvantages for each option [1,2].

Local random-pattern skin flaps have random perfusion pattern, limited size and arc of rotation and the need for skin grafting of the donor site. The reversed sural flap is another option, but plagued by the sensory loss at the lateral foot, the ugly grafted donor site, especially in females, and the high complications rate if there is co-morbid diseases as diabetes mellitus and peripheral vascular diseases [13,14].

Free tissue transfer is an excellent coverage option, but require microsurgical expertise, and has high complications rate in chronic cases due to the post-traumatic vessel disease [15,16].

Muscle flaps are valuable option for reconstruction of middle third leg defects. The soleus muscle can be used, but the defect will be covered by the least vascularised part of the flap, and the volume of the flap is often too small to fill the defect, in addition to sacrificing the whole or one lobe of the muscle [6]. The split tibialis anterior muscle flap can be also used, but its use is limited by its small size, limited mobility, contusion liability by the fractured tibia, making it ideal for narrow longitudinal pretibial defects only [8].

The bulk of the hemigastrocnemius flap performed in this study was more than enough to cover the defect. The single pedicle and detaching the muscle origin offered great flexibility and additional length. Denervation of the flap prevented it from possible breakdown and contractions pain due to muscle spasms [17].

Morbidity at the donor site was negligible. Loss of function of the gastrocnemius should not be a concern, as the soleus is the main flexor of the ankle [18]. Both gastrocnemius heads are expendable if the soleus is intact [19]. Function of the knee should not be affected either. Hamstring muscles are the prime flexors of the knee accounting for approximately 65% of its strength [20].

In 1983, Bashir [9] described successful use of distally based medial hemigastrocnemius flap for coverage of mid-tibial defects in three cases. Tarek

[10] successfully used the distally based hemigastrocnemius flap in covering middle third leg defects in 19 patients. Our results in this study as regards success and complications rate were comparable to that obtained by Tarek's study.

The consistency of the sural vessels and the anastomotic vessels between the two heads accounts for the reliability of the gastrocnemius muscle flap of both heads on a single vascular pedicle. The size of the flap, ease of dissection, and extended arc of rotation and reach are advantages. Contour deformity and functional deficit are minimal. So, this muscle flap seems to be a valuable option for middle third leg reconstruction.

## Conclusion:

The distally based hemigastrocnemius flap based on vascular communications between the two heads can be used for reconstruction of middle third leg defects. It provides a reliable and stable coverage for these defects without sacrificing a nerve or a major vessel to the foot. Functional deficit and contour irregularity are minimal.

## REFERENCES

- 1- MacKenzie E.J. and Bosse M.J.: Factors influencing outcome following limb-threatening lower limb trauma: Lessons learned from the Lower Extremity Assessment Project (LEAP). J. Am. Acad. Orthop. Surg., 14: 205, 2006.
- 2- MacKenzie E.J., Bosse M.J., Pollak A.N., et al.: Long-term persistence of disability following severe lower limb trauma: Results of a seven-year follow-up. J. Bone Joint Surg. Am., 87 (8): 1801, 2005.
- 3- Friedrich J.B., Katolik L.I., Hanel D.P., et al.: Reconstruction of soft tissue injury associated with lower extremity fracture. J. Am. Acad. Orthop. Surg., 19: 81, 2011.
- 4- Stark W.J.: The use of pedicled muscle flaps in the surgical treatment of chronic osteomyelitis resulting from compound fractures. J. Bone Joint Surg., 28 (A): 343, 1946.
- 5- Ger R.: The management of pretibial skin loss. Surgery, 36: 757, 1968.
- 6- Mathes S.J. and Nahai F.: Clinical applications of muscle and musculocutaneous flaps. St. Louis, Mosby, 1982.
- 7- Megahed M.A.: Function-sparing tibialis anterior pivoted muscle flap for reconstruction of post-burn and post-traumatic middle-third leg defects with exposed tibia. Ann. Burns Fire Disasters, 24 (2): 67, 2011.
- 8- Nikhik P., Parag S., Ganesh P., et al.: The split tibialis anterior muscle flap: A simple solution for longitudinal middle third tibial defects. Indian J. Plast. Surg., 45 (1): 53, 2012.
- 9- Bashir A.H.: Inferiorly-based gastrocnemius muscle flap in the treatment of war wounds of the middle and lower third of the leg. Br. J. Plast. Surg., 36: 307, 1983.



- 10- Tarek Kishk: Reconstruction of the middle third of the leg by distally based hemigastrocnemius muscle flap. Egypt. J. Plast. Reconstur. Surg., 43 (2): 181, 2010.
- 11- Tsetsonis C.H., Kaxira O.S., Laoukos D.H., et al.: The arterial communication between the gastrocnemius muscle heads: A fresh cadaveric study and clinical implications. Plast. Reconstur. Surg., 105: 94, 2000.
- 12- Tsetsonis C.H., Kaxira O.S., Laoukos D.H., et al.: The venous communication between the gastrocnemius muscle heads. Plast. Reconstur. Surg., 105: 1357, 2000.
- 13- Touam C., Rostoucher P., Bahatia A., et al.: Comparative study of two series of distally based fasciocutaneous flaps for coverage of the lower one fourth of the leg, the ankle, and the foot. Plast. Reconstur. Surg., 107: 383, 2001.
- 14- Steffen P.B., Roberto S., Detlev E., et al.: A realistic complication analysis of 70 sural artery flaps in a multi-morbid patient group. Plast. Reconstur. Surg., 112 (1): 129, 2003.
- 15- Codina M.: Early microsurgical reconstruction of complex trauma of the extremities. Plast. Reconstur. Surg., 78: 285, 1986.
- 16- Akland R.D.: Refinements in lower extremity free flap surgery. Clinics in Plastic Surgery, 17: 733, 1990.
- 17- Pico R., Luscher N.J., Romestch M., et al.: Why the denervated gastrocnemius muscle flap should be encouraged. Ann. Plast. Surg., 26: 312, 1991.
- 18- Tobin G.R.: Soleus flaps. In: Strauch B., Vasconez L.O., Hall Findlay E.J. (Eds.). Grabb's Encyclopedia of Flaps. 1<sup>st</sup> ed. Boston: Little Brown Company, pp: 1706-11, 1990.
- 19- Mathes S.J. and Nahai F., editors.: Reconstructive Surgery: principles, anatomy, and technique. NewYork: Churchill Livingstone, pp: 1391-48, 1997.
- 20- Mar Khede G. and Stener B.: Function after removal of various hip and thigh muscles for extirpation of tumors. Acta. Orthop. Scand., 52: 373, 1981.